



## Penile Extra-Tunical Graft Reconstruction of Peyronie's Disease Concavity Deformities

Linley Diao, Maia E. VanDyke, Gregory A. Joice, Zachary B. Lewis, Benjamin M. Dropkin, Sarah C. Sanders, Steven J. Hudak, and Allen F. Morey

<b>OBJECTIVES</b>	To report our initial experience with the extra-tunical grafting (ETG) procedure. This procedure was recently introduced by UCSF investigators as a tunica-sparing technique for management of penile concavity deformities.
<b>METHODS</b>	We retrospectively reviewed records of patients who underwent ETG at our tertiary-care referral center between 2017 – 2020. A collagen graft made from bovine pericardium (Lyopiant) was placed overlying the defect without violating the tunica albuginea or mobilizing the neurovascular bundle. The stretched penile length (SPL) and circumference at the location of deformity were measured intra-operatively. Patient reported outcomes were evaluated by an anonymous 10-question online survey.
<b>RESULTS</b>	19 men underwent ETG with a median follow-up of 59 (IQR: 24 – 708) days. ETG was performed via either a window (15/19, 78%) or a de-gloving (4/19, 21%) incision with concomitant penile plication performed in 16/19 (84%) patients. Penile circumference increased by an average of 1.4 cm + 0.5 ( $P = 0.03$ ) at the location of deformity, while pre- and post-operative SPL were similar (14.0 + 1.4 vs 14.0 + 1.3 cm, $P = 0.95$ ). Overall patient satisfaction was reported by 13/15 (86%) patients. Twelve out of 15 (80%) patients reported concavity deformity to be “improved”, with 73% reporting “much better”. Among 8 patients with follow up greater than six months, graft palpability was reported in 4/8 (50%) patients but was not bothersome.
<b>CONCLUSION</b>	The ETG procedure appears to be safe and effective for the treatment of penile concavity deformities. Patient outcomes and satisfaction are favorable at intermediate follow up. UROLOGY 158: 237–242, 2021. © 2021 Elsevier Inc.

Peyronie's Disease (PD) is an acquired idiopathic connective tissue disorder involving formation of a fibrotic plaque within the tunica albuginea of the corpus cavernosum.<sup>1,2</sup> The prevalence of PD is estimated to be 0.5%–20% depending on study and patient population.<sup>1</sup> PD has been shown to negatively impact self-perception of physical and sexual attractiveness.<sup>3–5</sup>

Penile concavity deformities (notching and hourglass) are particularly troubling for patients and are estimated to be present in 10% of PD cases.<sup>6</sup> Notching results from a volume-loss deformity that may destabilize the axial rigidity of the erect penis.<sup>6</sup> Hourglass deformity results from bilateral notching and causes circumferential narrowing of the tunica albuginea.<sup>7</sup> Traditionally, plaque incision/excision and grafting (PIG/PEG) has been the surgical

procedure of choice for men with penile concavity deformities.<sup>8</sup> However, PIG/PEG requires violation of the tunica albuginea and mobilization of the neurovascular bundle potentially leading to postoperative erectile dysfunction (ED) or altered penile sensation.

The extra-tunical grafting (ETG) technique was first described in 2017 by UCSF investigators as a tunica-sparing surgical procedure to be utilized in the treatment of PD concavity deformities.<sup>9</sup> ETG was designed to reinforce the tunica albuginea with a graft that improves penile stability and cosmesis. The neurovascular bundle is not mobilized, and integrity of the tunica albuginea is maintained, which mitigates the risk of postoperative hypoesthesia and *de novo* ED.<sup>9</sup> Here we examine our experience with the ETG procedure to evaluate patient reported outcomes of this promising new technique.

**Financial Disclosure:** Dr. Allen Morey receives honoraria for being a guest lecturer/meeting participant for Boston Scientific and Coloplast Corp.

From the Department of Urology, University of Texas Southwestern Medical Center, Dallas, Texas

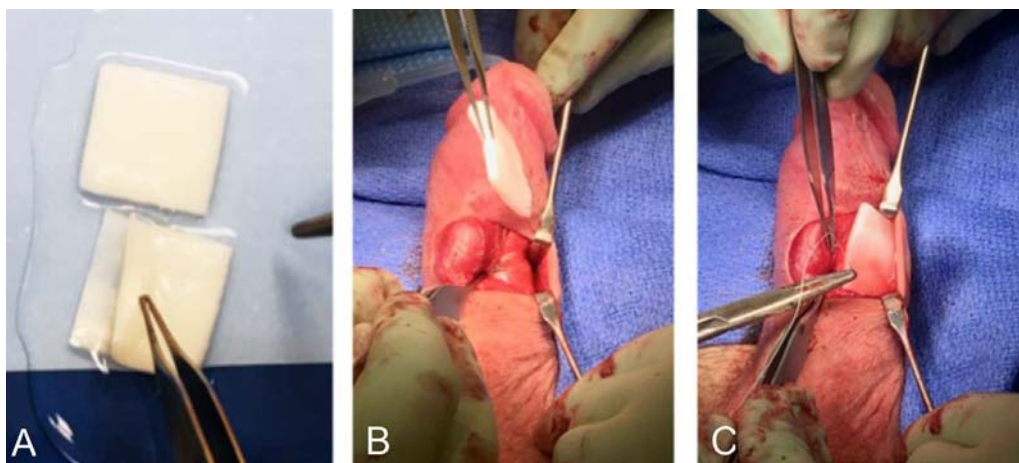
Address correspondence to: Allen F Morey, M.D., Department of Urology, University of Texas Southwestern Medical Center, 2001 Inwood Rd, Dallas, TX 75390-9110. E-mail: allen.morey@utsouthwestern.edu

Submitted: May 25, 2021, accepted (with revisions): July 14, 2021

## MATERIALS AND METHODS

### Patient Selection and Data Collection

After Institutional Review Board approval, a retrospective chart review was performed on all patients who underwent penile



**Figure 1.** (A) A collagen graft made from bovine pericardium (Lyoplast) was arranged on the back table in a 'postage stamp' fashion. The graft is placed overlying the defect without violating the tunica albuginea (B) and sutured in place (C). (Color version available online.)

ETG for reconstruction of PD concavity deformities. Procedures were performed by a single surgeon (AFM) at our tertiary-care referral center between October 2017 and November 2020. All patients presented preoperatively with the ability to achieve an erection adequate for sexual intercourse with or without medication. The presence, or lack, of preoperative ED was recorded. No patients underwent any concomitant therapies for ED.

Information regarding penile curvature and type of deformity was ascertained in clinic with photographs of a rigid erection provided by the patient. Intraoperative data included concomitant procedures, type of incision (de-gloving or window), change in stretched penile length (SPL), and change in circumference at location of deformity. Patient reported outcomes including overall satisfaction, graft palpability, change in erectile function, and improvement in curvature and concavity deformities were evaluated by an anonymous ten-question online survey.

### Operative Technique for Concavity Deformities

Extratunical grafting is performed in the outpatient surgery center (OSC) under general anesthesia most commonly with a laryngeal mask airway (LMA). Patients are positioned on the operating room table in the supine position and 20 mcg alprostadil (Edex) is administered intracorporally to induce a pharmacologic erection. Injectable saline is utilized as needed for patients with minimal response to alprostadil to create a fully rigid erection. SPL and girth are measured prior to starting the procedure.

The choice of surgical incision is determined based on the location and extent of deformities. For patients with unilateral plaques, we prefer a 'window' technique with a 3 – 4 cm longitudinal incision over the defect. This incision gives adequate exposure to the tunica albuginea for placing the graft material and can be moved along the penile shaft as needed for plication sutures. For bilateral and extensive deformities (especially those without curvature), we perform a circumcising incision to fully expose the tunica albuginea to allow for placement of multiple grafts into the defects. We prefer to perform a 'window' technique whenever possible to decrease risk of penile skin lymphedema and hasten patient recovery.

The chosen incision is made sharply and dissection is performed through dartos and Buck's fascia to expose the tunica

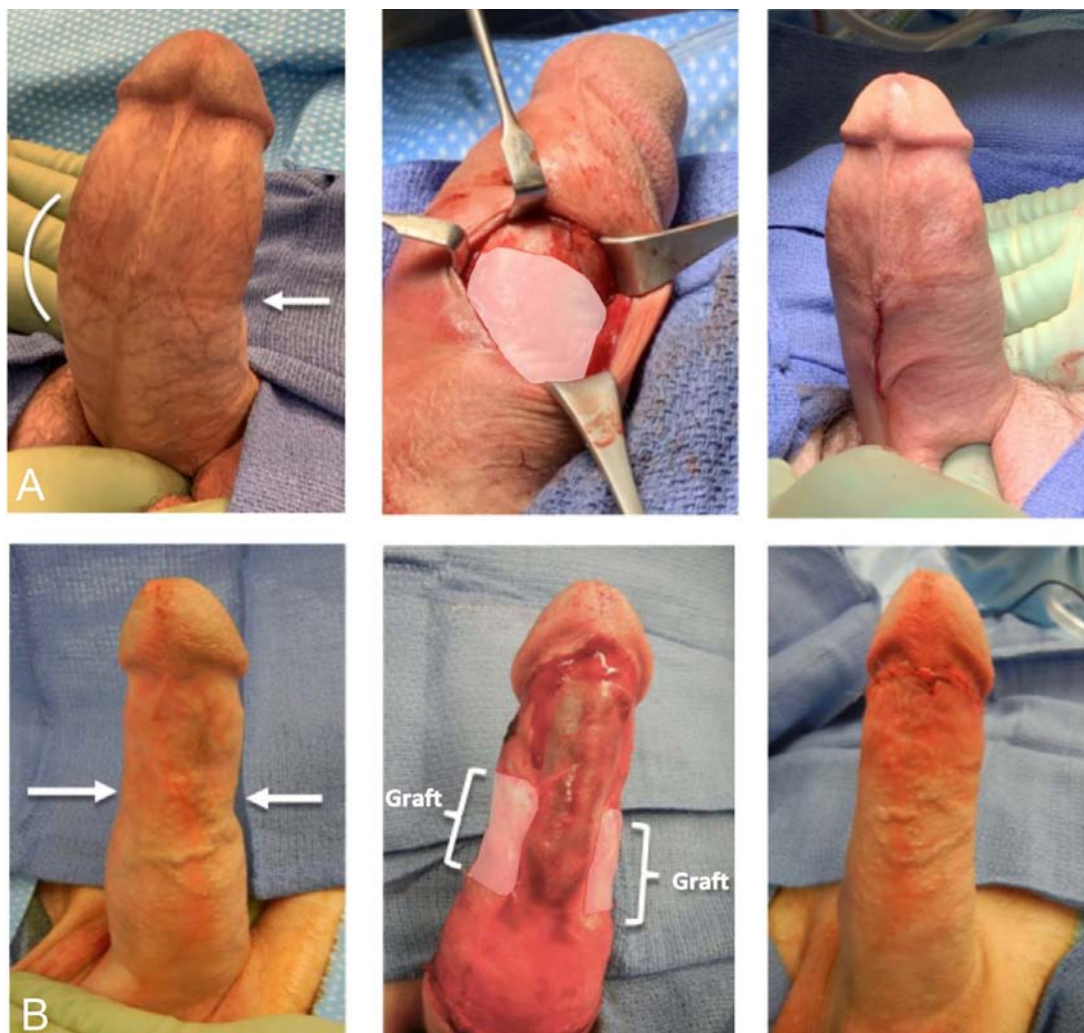
albuginea. The defect is measured for both length and width. If patients have concomitant curvature, this is corrected using a series of braided permanent (2 – 0 Ethibond) sutures. On the back table, an appropriately sized collagen graft (bovine pericardium, Lyoplast) is prepared in a single layer or "postage stamp" fashion (Fig. 1). This graft is then inserted into the deformity and secured with monofilament absorbable suture (4 – 0 Monocryl). Multiple layers of graft can be fashioned and stacked to completely fill in the defect until it is symmetric with the contralateral side.

In the case of complex defects, various sizes of grafts may need to be stacked in order to optimally fill out the indentation. For bilateral defects, a circumferential graft can be utilized in an omega shape to spare covering the corpus spongiosum as previously described.<sup>9</sup> Once completed, the penis is examined closely for symmetry and cosmesis and fine alterations can be made if needed. We err on the side of slightly larger grafts to compensate for graft resorption during the perioperative period.

For patients with penile curvature undergoing concomitant penile plication, this was performed by placing a series of plication sutures along the opposing side of the curvature to straighten the penis. For patients with dorsal penile curvature, we made a ventral incision and dissected along either side of the spongiosum and the ventrolateral tunica albuginea. There we place multiple parallel sutures along the ventrolateral penile shaft, beginning proximally and continuing distally to correct dorsal curvature.

The incision is irrigated, and meticulous hemostasis is achieved. Buck's fascia is reapproximated with absorbable suture (4 – 0 Monocryl) ensuring that there is no entrapment of the shaft skin. For window incisions, the skin is closed in a subcuticular fashion with surgical glue (Dermabond) to minimize scar formation. In the case of circumcising incisions, the mucosal collar is trimmed to prevent lymphedema and the skin closed with simple interrupted sutures. Finally, SPL and penile girth are remeasured and compared to preoperative values (Fig. 2).

A non-adherent dressing is placed and the penis is gently wrapped in Coban dressing to prevent swelling. The entire procedure typically takes less than 1 hour and patients are discharged to home the same day without specific work restrictions. Patients are instructed to exchange their dressing daily for 1 – 2 weeks and abstain from sexual activity for 5



**Figure 2.** (A) Patient with unilateral concavity deformity and penile curvature treated with ETG and concomitant penile plication via window incision. (B) Patient with bilateral concavity deformities treated with ETG via circumcising incision. (Color version available online.)

weeks. Clinic follow up is arranged at 5 weeks postoperatively and patients are assessed for satisfaction with erections, curvature, and penile girth. Assuming adequate wound healing, patients are cleared to return to sexual activity and follow up as needed.

## RESULTS

### Demographics and Intraoperative Data

From October 2017 to November 2020, 19 patients underwent ETG for treatment of PD concavity deformities with a median follow-up of 59 (IQR: 24 – 708) days. The mean patient age was  $53 \pm 13$  years and 11/19 (58%) patients presented with hourglass deformity. Details regarding pre-op deformities, curvature, and the amount of graft material used can be found in [Supplementary Table 1](#). Patient comorbidities were recorded as follows: hypertension (42%), diabetes mellitus (31%), hyperlipidemia (21%), coronary artery disease or myocardial infarction (15%), Dupuytren's contracture (5%), gunshot wound (5%), stroke (5%), deep vein thrombosis (5%), prior surgical intervention for PD (5%) ([Supplementary Table 2](#)).

Mean preoperative penile curvature was found to be  $42^\circ \pm 16^\circ$  ([Table 1](#)). Penile plication was performed concomitantly in

16 out of 19 (84%) patients with bothersome preoperative penile curvature. ETG was performed using a window incision for 15 (79%) patients, while a degloving incision was used for 4 (21%) patients. Penile circumference increased by an average of  $1.4 \text{ cm} \pm 0.5$  ( $P = 0.03$ ) at the location of deformity and there was no significant change between pre- and post-operative SPL ( $14.0 \pm 1.4$  vs  $14.0 \pm 1.3$  cm,  $P = 0.95$ ).

**Table 1.** Intra-operative variables and outcomes after extra-tunical grafting

Measure	Average	St. Dev.
Curvature	$42^\circ$	$16^\circ$
SPL Before	14.0 cm	1.4 cm
SPL After	14.0 cm	1.3 cm
SPL Change	0.03 cm	0.2 cm ( $P=0.95$ )
Girth Before	10.9 cm	1.3 cm
Girth After	12.2 cm	1.4 cm
Girth Change	1.4 cm	0.5 cm ( $P=0.03$ )

Standard Deviation (St. Dev.)  
SPL (stretched penile length)



## Patient Reported Outcomes

Fifteen patients (79%) responded to the online survey at an average of 240 days after surgery. Overall patient satisfaction was reported by 13/15 (87%) patients. Twelve out of 15 (80%) patients reported concavity deformity to be improved, with 73.3% reporting the deformity to be “much better” (Supplementary Figure). An improvement in erectile function was reported in 11/15 (73%) patients, while 2/15 (13%) patients noted no change in erectile function. Of the 8 patients that had follow up greater than six months after surgery, graft palpability was reported in 4/8 (50%) patients but was not bothersome. One patient (5%) reported penile hypoesthesia at post-op clinic visit. No patient experienced penile pain that persisted after the immediate post-operative period.

There was one postoperative complication of a penile hematoma (Clavien-Dindo Grade I) in a patient that received concomitant circumcision. The hematoma resolved without any additional intervention and this patient reported that he was overall satisfied with the procedure at most recent follow up. There were no cases of postoperative graft rejection or infection.

## DISCUSSION

### ETG Rationale

Few options exist for treating patients with significant bothersome penile concavity deformities. PIG/PEG is a well-studied option, that has been shown to be effective in treating these patients.<sup>10,11</sup> However, PIG/PEG requires dissection of the neurovascular bundle (NVB) and incision into the tunica albuginea. This tunica violation can lead to intracavernosal fibrosis and loss of veno-occlusive function at the area of grafting potentially leading to ED.<sup>12,13</sup> In one study of grafting for PD concavity deformities, 17% of patient reported penile hypoesthesia and all patients had mild worsening erectile function, particularly penile rigidity, at 5-year follow up.<sup>14</sup>

ETG is notably unique in that the tunica and neurovascular bundle are spared, therefore lowering the risk of hypoesthesia, perception of penile shortening, and *de novo* ED. In the current study, the majority of patients (87%) noted either improvement or no change in postoperative erectile function and there was only one report (5%) of altered penile sensation in our series. Importantly, there was also no significant change in SPL after ETG despite a significant improvement in penile circumference. Along with our overall high satisfaction rate, this study suggests that ETG is a safe and effective procedure for patients with concavity deformities.

We and others have utilized lyophilized bovine pericardium (LBP, Lyoplast) successfully in prior penile grafting studies with good results.<sup>15</sup> LBP is an ideal grafting material for this indication as it has low immunogenicity, high tensile strength, excellent elasticity and flexibility.<sup>15</sup> LBP is enzymatically degraded and substituted with the recipient's connective tissue to create a realistic consistency and morphology. Lyoplast is utilized in neurosurgery as a dura mater substitute due to these advantageous characteristics and is an ideal biomaterial for ETG. Autologous grafts can be used but increase operative time needed to harvest

while also increasing postoperative morbidity. The relative scarcity of harvest sites for autologous grafts limits the ability to customize grafts for complex or large deformities. Common complications of autologous grafts include wound healing disorders, infection, scarring, swelling, pain, numbness, and lymphedema. Synthetic grafts are not recommended due to risks of infection, inflammation, allergic reaction, rejection, fibrosis, and contracture.<sup>11,16</sup>

### Patient Selection

Ideal patients for ETG are men with penile concavity deformities who present in the stable phase of the disease with good erectile function. The majority of patients will also have some degree of penile curvature requiring concomitant penile plication. In our study, 84% of men underwent repair of both penile curvature and concavity deformity simultaneously with overall good satisfaction results. Additionally, in the majority of cases we were able to correct both deformities via a window incision to avoid increased operative time and wound healing.

Many patients elect for treatment with intracavernosal collagenase clostridium histolyticum (CCH; Xiaflex) to correct penile curvature. While this treatment can be effective in improving penile curvature, it has no impact on indent deformities.<sup>17-19</sup> Although not observed in this study, ETG would be ideal for patients with prior CCH treatment since it does not violate the tunica albuginea which may be altered from multiple injections.

All men in this series were preoperatively able to obtain a rigid erection sufficient for sexual intercourse with or without medical treatment. Our results showed that the majority of patients (87%) noted either improvement or no change in postoperative erectile function. This finding is consistent with the design of ETG being ideal for preserving erectile function by not violating the tunica albuginea while correcting indentation deformities. In patients with pre-existing ED and PD, AUA guidelines recommend penile prosthesis placement with adjunctive intra-operative procedures to correct penile deformity.<sup>1</sup> In this scenario, ETG could be employed in addition to penile prosthesis insertion to improve penile cosmesis. Our finding of no graft infections within the cohort is encouraging that ETG would add minimal morbidity to prosthesis insertion.

### Limitations

ETG is a newly described procedure, and this is only the second known published series on the technique. limitation of the ETG technique is that the PD plaque is left in-situ so it is possible that with severe hinge defects, patients may still experience some erectile instability postoperatively. However, we feel that the benefits of preserved erectile function and overall safety outweigh the theoretical risk of residual instability. This study is limited by its overall retrospective nature and small sample size. Patients were followed on an as-needed basis after their 6-week postoperative visit and thus median follow up was only 59 days. However, survey follow-up was notably longer, with an average of 240 days.

Although more long-term data would improve this study, we feel that the combination of intermediate and patient reported outcomes with this new technique offers an important addition to the current data on treating PD concavity deformities. Partner satisfaction was not tracked in the reported outcomes, but would be a beneficial factor to measure in future studies. Penile duplex ultrasonography is not readily available at our institution and thus we do not routinely perform preoperative pharmacologic erections. However, a rigid erection was induced at the beginning of all cases to allow for precise evaluation of curvature and indentation at the time of correction.

This study utilized 1 type of graft (Lyoplant) for all study patients. It would be beneficial to compare and contrast outcomes with different graft materials in future studies with a randomized control trial. Finally, the generalizability of this study may be limited as it reflects a single surgeon at a tertiary care referral center with extensive experience in surgical treatment for PD. Ideally, future studies will utilize larger cohorts with longer follow-up and will incorporate data from multiple institutions.

## CONCLUSION

The ETG procedure appears to be a straightforward, safe, and effective procedure for the treatment of penile concavity deformities. Patient reported outcomes and satisfaction are favorable at intermediate follow-up. ETG should be an important component in the armamentarium of urologists treating Peyronie's disease.

## SUPPLEMENTARY MATERIALS

Supplementary material associated with this article can be found in the online version at <https://doi.org/10.1016/j.urology.2021.07.039>.

## References

1. Nehra A, Alterowitz R, Culkin DJ, et al. Peyronie's disease: AUA guideline. *J Urol*. 2015;194:745–753.
2. Haag SM, Hauck EW, Eickelberg O. Investigation of the Antifibrotic Effect of IFN- $\gamma$  on Fibroblasts in a Cell Culture Model of Peyronie's disease. *Eur Urol*. 2008;53:425–430.
3. Rosen R, Catania J, Lue T, et al. Impact of Peyronie's disease on sexual and psychosocial functioning: qualitative findings in patients and controls. *J Sex Med*. 2008;5:1977–1984.
4. Terrier JE, Nelson CJ. Psychological aspects of Peyronie's disease. *Transl Androl Urol*. 2016;5:290–295.
5. Paulis G, Romano G, Paulis A. Prevalence, psychological impact, and risk factors of erectile dysfunction in patients with Peyronie's disease: a retrospective analysis of 309 cases. *Res Rep Urol*. 2016;8:95–103.
6. Margolin EJ, Pagano MJ, Aisen CM, et al. Beyond Curvature: prevalence and characteristics of penile volume-loss deformities in men with Peyronie's disease. *Sex Med Today*. 2018;6:309–315.
7. Cakan M, Akman T, Oktar T, et al. The clinical characteristics of Peyronie's Patients with Notching Deformity. *J Sex Med*. 2007;4:1174–1178.
8. Yafi FA, Hatzichristodoulou G, Wang J, et al. Outcomes of surgical management of men with Peyronie's disease with hourglass deformity. *Urology*. 2016;91:119–123.

9. Reed-Maldonado AB, Alwaal A, Lue TF. The extra-tunical grafting procedure for Peyronie's disease hourglass and indent deformities. *Transl Androl Urol*. 2018;7:S1–S6.
10. Segal RL, Burnett AL. Surgical management for Peyronie's disease. *World J Mens Health*. 2013;31:1–11.
11. Kadioglu A, Küçükduymaz F, Sanli O. Current status of the surgical management of Peyronie's disease. *Nat Rev Urol*. 2011;8:95–106.
12. Leungwattanakij S, Bivalacqua TJ, Caulfield JJ, et al. Evaluation of cadaveric pericardium in the rat for the surgical treatment of Peyronie's disease. *Urology*. 2000;56:1075–1080.
13. Leungwattanakij S, Bivalacqua TJ, Reddy S, et al. Long-term follow-up on use of pericardial graft in the surgical management of Peyronie's disease. *Int J Impot Res*. 2001;13:183–186.
14. Chung E, Clendinning E, Lessard L, et al. 5-year follow-up of Peyronie's graft surgery: outcomes and patient satisfaction. *J Sex Med*. 2011;8:594–600.
15. Gelbard M, Goldstein I, Hellstrom WJG, et al. Clinical efficacy, safety and tolerability of collagenase clostridium histolyticum for the treatment of peyronie disease in 2 large double-blind, randomized, placebo controlled phase 3 studies. *J Urol*. 2013;190:199–207.
16. Hellstrom WJG, Kendirci M, Matern R, et al. Single-blind, multicenter, placebo controlled, parallel study to assess the safety and efficacy of intralesional interferon  $\alpha$ -2b for minimally invasive treatment for Peyronie's disease. *J Urol*. 2006;176:394–398.
17. Kendirci M, Usta MF, Matern RV, et al. The impact of intralesional interferon  $\alpha$ -2b injection therapy on penile hemodynamics in men with Peyronie's disease. *J Sex Med*. 2005;2:709–715.
18. Otero J, Gómez B, Polo J, et al. Use of a lyophilized bovine pericardium graft to repair tunical defect in patients with Peyronie's disease: experience in a clinical setting. *Asian J Androl*. 2017;19:316–320.
19. Brannigan RE, Kim ED, Oyasu R, et al. Comparison of tunica albuginea substitutes for the treatment of Peyronie's disease. *J Urol*. 1998;159:1064–1068.

## EDITORIAL COMMENT

Penile “hourglass” deformity (PHD) is a rare condition that affects about 1% of patients with Peyronie's disease.<sup>1</sup> PHD develops from the Peyronie's disease plaque and the *tunica albuginea* retraction due to the inflammatory process. The final aspect of a penis during tumescence consists of a “clepsydra” shaped shaft and a subsequent psychological and functional impact on the relational life of the patients.<sup>2</sup> Erectile dysfunction was reported in 61% – 68% of the patients although it is not clear if this dysfunction could be considered as psychologically or anatomically related.<sup>1–2</sup>

The authors of the present manuscript described a novel experimental surgical technique in a pilot study on 19 patients. Patients were monitored by an online survey as well as a visit. The PHD was described as improved in 73.3% of responders to the online questionnaire and 73% of them reported an implemented penile tumescence for sexual intercourse.<sup>3</sup> Not only were previous surgeries on the Peyronie's disease plaques not correctly described except for a table out of the text, but also the reason for such implementation was not adequately discussed by the authors. Information regarding the psychological condition of patients with PHD was not included in the text; no questionnaires (PDQ, IIEF or VAS scale) were submitted to the patients before or after surgery in order to understand the patients' real condition before operation or to define the real results.<sup>4</sup>

Moreover, no previous studies described the extra-tunical application of grafts to improve the cosmetic aspects of the penile shaft affected by PHD since the papers to which the



authors refer are those relating to corporoplasty with the incision/excision of plaques and the grafting of pericardium. In general, however, it may be assumed that the application of artificial patches where hypovascularity is present induces a long term lack of both adhesion and endothelialization tissues (no blood support means no endothelialization) and the subsequent risk that the patches migrate toward other sites of the same organ especially if the patch is fixed with absorbable sutures.<sup>5,6</sup>

The lack of any long term follow up as well as missed clinical check-ups for each patient who received this innovative implant does not allow an effective and definitive result in terms of reliability and safety. On the other hand the application of this technique would seem to be more straightforward and more viable in comparison to the more invasive alternative surgeries. Nonetheless, the effects of such surgery should be appropriately compared to other techniques of plaque removal and tunica albuginea substitution, in randomized controlled trials with an appropriate number of randomized patients. This is the only undisputable method to obtain definitive responses in terms of safety and long term efficacy.

**Riccardo Bartoletti, Girolamo Morelli, Alessandro Zucchi**, Department of Translational Research and New Technologies in Medicine and Surgery, University of Pisa – Italy

## References

1. Kendirci M, Nowfar S, Gur S, et al. The relationship between the type of penile abnormality and penile vascular status in patients with Peyronie's disease. *JUrol.* 2005;174:632–635.
2. Cakan M, Akman T, Oktar T. The clinical characteristics of Peyronie's patients with notching deformity. *JSex Med.* 2007;4:1174–1178.
3. Diao L, Van Dyke ME, Joice GA, et al. Penile extra-tunical grafting reconstruction of Peyronie's disease concavity deformities. *Urology.* 2021.
4. Hellstrom WJ, Feldman RA, Coyne KS, et al. Self-report and clinical response to Peyronie's disease treatment: Peyronie's disease questionnaire results from a large double-blind randomized placebo-controlled phase 3 study. *Urology.* 2015;86:291e–299e.
5. Burkhard MD, Dietrich M, Andronic O, et al. Arthroscopic repair of posterolateral rotator cuff tears with bioabsorbable patch

augmentation: a magnetic resonance-controlled case series with 1-year follow-up. *JSES Int.* 2020 Sep 9;4:860–868. <https://doi.org/10.1016/j.jseint.2020.07.019>.

6. Li X, Guo Y, Ziegler K, et al. Current usage and future directions for the bovine pericardial patch. *Ann Vasc Surg.* 2011;25:561–568. <https://doi.org/10.1016/j.avsg.2010.11.007>.

<https://doi.org/10.1016/j.urology.2021.07.041>  
UROLOGY 158: 241–242, 2021. © 2021 Elsevier Inc.



## AUTHOR REPLY

After years of emphasizing only penile straightening procedures in our Peyronie's reconstruction cases, our patients have taught us that penile concavity deformities (notching and hourglass) are often just as troubling. The extra-tunical grafting (ETG) technique is a promising innovation for addressing these deformities and our series is only the second known published series on the technique. Preservation of the tunica albuginea avoids disruption of the veno-occlusive apparatus at the area of grafting, thus likely lowering the risk of complications.

This is a preliminary study that highlights the safety and efficacy of the ETG procedure. Overwhelmingly, patients (and surgeons) were pleased with results both quantitatively and qualitatively. Although more long-term data is needed, we feel that the combination of intermediate and patient reported outcomes presented herein suggest this technique is effective for treatment of Peyronie's Disease concavity deformities.

**Linley Diao, MD, Allen F. Morey, MD**, Department of Urology, University of Texas Southwestern Medical Center, Dallas, Texas

<https://doi.org/10.1016/j.urology.2021.07.040>  
UROLOGY 158: 242, 2021. © 2021 Elsevier Inc.